



---

## **Carvedilol Could Ameliorate Acetaminophen Overdose Hepatotoxicity. Endogenous H<sub>2</sub>S Contributes Such Effect: A Comparative Biochemical Evaluation**

**Mona M. Allam, Abeer A. Shoman**

Physiology department, Faculty of Medicine, Benha University, Egypt

**\*Corresponding Author**

Mona Maher Allam

Faculty of Medicine

Benha University

Egypt

Cell no. +00201005413002

Email: monamaher8011@yahoo.com

*Received: 29 December 2016; / Revised: 9 March 2017; / Accepted: 13 March 2017*

---

### **Abstract**

This study was designed to evaluate the effect of acute overdose of acetaminophen exposure, and determine the curative effect of carvedilol and explore the role of endogenous H<sub>2</sub>S. Four groups of rats (n=10): groups I: control group, group II: acetaminophen (APAP) hepatotoxic group, group III: APAP hepatotoxic + carvedilol (CVD) treated group and group IV: APAP hepatotoxic + CVD + hydrogen sulfide (H<sub>2</sub>S) blocker; dl-propargylglycine (PAG) treated group. Animals of groups II, III, IV were given a single overdose of APAP; (2 g/kg) by oral gavages. Groups III and IV received CVD (10 mg/kg/day) by oral gavages, treatment was started 1 hr before APAP administration for 14 days. Animals of group IV received intraperitoneal injection of PAG (45 μmol/kg/day) for 14 days before CVD administration. On the 15th day, blood samples were obtained for estimation of liver enzymes activity levels and animals were sacrificed. Liver was extracted for histological examination and estimation of antioxidant enzymes activity and malondialdehyde (MDA) levels in liver tissue homogenate. Serum liver enzymes activity and MDA levels were significantly higher with significantly lower antioxidant enzymes activity in group II than in groups I and III. Serum liver enzymes activity and MDA levels were significantly higher with reduced antioxidant enzymes activity in group IV than in group III. We concluded that acute acetaminophen exposure destroyed hepatic architecture and altered enzymes activity. Carvedilol has a curative effect through preserved activity of antioxidants. Endogenous H<sub>2</sub>S significantly contributes to carvedilol mediated effect.

**Keywords:** Acetaminophen, Hepatotoxicity, Carvedilol, Hydrogen Sulphid, Antioxidant enzymes

---

**Abbreviations:** (ALF): Acute liver failure; (APAP): N-Acetyl-p-Aminophenol; (CVD): Carvedilol; (H<sub>2</sub>S): Hydrogen sulfide; (CSE): cystathionine  $\gamma$ -lyase; (PAG): dl-propargylglycine; (ALT): alanine aminotransferase; (AST): aspartate aminotransferase; (GSH): glutathione; (MDA): malondialdehyde; (GPx): glutathione peroxidase; (CAT): catalase; (SOD): superoxide dismutase.

## 1. Introduction

Acute liver failure (ALF) can be the result of different etiologies, with most cases caused by drug-induced hepatotoxicity. Despite advances in this field, the management of ALF continues to be one of the most challenging issues in clinical medicine [1].

N-Acetyl-p-Aminophenol (APAP; acetaminophen) is one of the most commonly used drugs for pain relieving and antipyretic purposes on a worldwide basis. It is safe and effective at recommended doses, however overdose or chronic use of high-dose acetaminophen has the potential for inducing hepatotoxicity and ALF. It is easily accessible over the counter and thus intentional paracetamol overdose is common [2].

Acetaminophen toxicity causes ALF by inducing centrilobular hepatic damage as a consequence of mitochondrial oxidative stress [3]. Multiple drugs and natural products were tried to overcome or ameliorate oxidative stress; paeonol was found to have a protective ability against APAP-induced hepatotoxicity and might be an effective candidate compound against drug-induced ALF [4]. An antioxidative nanoparticle was suggested to possess effective hepatoprotective properties and does not exhibit the notable adverse effects [5].

Adrenergic modulation of chemical-induced hepatotoxicity has been recognized for several decades, several studies were performed on different hepatotoxic models have demonstrated the ability to diminish hepatotoxicity via adrenergic blockade and adrenalectomy [6], also further studies demonstrated the potentiation of toxicity following administration of catecholamines, adrenergic agonist co-

administration, and electrical or physical stimulation of the nervous system [7].

Carvedilol (CVD) blocks sympathetic neural activation via antagonism of  $\beta_1$ -,  $\beta_2$ -, and  $\alpha_1$ -adrenoreceptors [8]. CVD provides greater cardiovascular benefits than traditional  $\beta$ -blockers that have been attributed to its antioxidant, anti-inflammatory, and anti-fibrotic properties [9]. The anti-fibrotic effects of CVD have been associated with the amelioration of oxidative stress in carbon tetrachloride-induced hepatotoxicity model [10] and suppression of hepatic satellite cell-derived lipogenesis- and fibrogenesis-related mediators [11].

Hydrogen sulfide (H<sub>2</sub>S) a naturally occurring colorless gas produced by both cystathionine- $\gamma$ -lyase (CSE) and cystathionine- $\beta$ -synthase (CBS), which use L-cysteine as a substrate to produce H<sub>2</sub>S. It has long been considered a toxic gas and environmental hazard. However, evidences show that H<sub>2</sub>S plays a great role in different physiological and pathological activities, and it exhibits distinctive impacts when applied at various doses [12]. H<sub>2</sub>S is a novel gasotransmitter that has been shown to exert an important role in regulating vascular tone [13]. There is a rapidly expanding body of evidence for important roles of H<sub>2</sub>S in protecting against tissue injury, reducing inflammation, and promoting repair [14]. In animal studies, H<sub>2</sub>S has been shown to play a role in both promoting and inhibiting inflammation and appears to increase survival in animal model of sepsis and shock [15]. The current study aimed to evaluate the toxic effect of acute exposure to overdose of acetaminophen in animal model and to determine the curative effect of carvedilol on such toxicity. The study also tried to explore if this effect is possibly mediated through the endogenous H<sub>2</sub>S through pre-treatment administration of a H<sub>2</sub>S-blocker dl-propargylglycine (PAG).

## 2. Materials and Methods

### 2.1 Animals

The present study included 40 male albino rats with weight range of 250-300 g obtained from Faculty of Agriculture, Moshtohor. Rats were grouped and kept in separate animal cages five rats in each, under the prevailing atmospheric conditions and room temperature. Animals were maintained on a balanced diet and fresh-water supply with normal light/dark cycle. At the end of the experiment and after collection of the samples we got rid of the animals in the incinerator of Benha University Hospital.

### 2.2 Experiment Design

The current prospective comparative study was conducted at Department of Physiology, Faculty of Medicine, Benha University. The study protocol was approved by the Local Ethical Committee, Benha Faculty of Medicine. Animals were divided randomly into 4 equal groups (n=10): group I: control group, group II: acetaminophen (APAP) hepatotoxic group, group III: APAP hepatotoxic + carvedilol (CVD) treated group, group IV: APAP hepatotoxic + CVD + (CSE) inhibitor; propargylglycine (PAG) treated group. Animals of groups II, III, IV were given a single overdose of APAP; (2 g/kg) [16] dissolved in saline by oral gavages. Groups III and IV received carvedilol (CVD) dissolved in saline which was given in a dose of 10 mg/kg/day by oral gavages, treatment was started 3 hr after APAP administration for 14 days [17]. Animals of group IV received intraperitoneal injection of cystathionine  $\gamma$ -lyase (CSE) inhibitor; propargylglycine (PAG) that was dissolved in saline, in a dose of 45  $\mu$ mol/kg/day [18] for 14 days before CVD administration. Animals of group I and II received normal saline by oral gavages and intraperitoneal injection for 14 days. If an animal died spontaneously or secondary to APAP toxicity, it was replaced by another so as to keep the number of study animals. On the 15<sup>th</sup> day, animals were anaesthetized with urethane (1.5 g/kg; i.p.) before being sacrificed by decapitation.

Blood samples were collected through cardiac puncture from all animals, then abdominal cavity was opened immediately and liver was extracted and its wet weight was determined. The liver was divided into two parts: the 1<sup>st</sup> part was preserved in 10% buffered formalin, (pH 7.8) for histological examination. The 2<sup>nd</sup> part of the liver was homogenized using a Mixer Mill MM400 (Retsch, Germany) in phosphate buffer (pH 6-7) and tissue homogenates were centrifuged at 10,000 x g, 4°C for 15 min.

### 2.3. Chemicals used

Acetaminophen (Paracetamol) was purchased from Eipico Co., 10th of Ramadan City, Egypt. Carvedilol was purchased from Global Napi Pharmaceuticals, Egypt. DL-propargylglycine (PAG) was purchased from Sigma Aldrich, USA.

### 2.4. Biochemical analysis

Blood samples were centrifuged at 3000 x g, 4°C for 10 min and supernatant was obtained for spectrophotometric estimation of serum alanine aminotransferase (ALT) and aspartate aminotransferase (AST) activity levels by Reitman and Frankel Method using kits obtained from Abcam, Cambridge, UK [19].

The prepared liver homogenate was divided into three parts:

- The 1<sup>st</sup> part was deproteinized with ice-cooled 12% trichloroacetic acid, centrifuged at 1000 x g. Supernatant was separated and stored at -20°C till be assayed for estimation of reduced glutathione (GSH) activity using Cayman GSH assay (Cayman Chemical Co., Ann Arbor, MI, USA) [20].

- The 2<sup>nd</sup> part was centrifuged at 1600 x g for 10 min at 4°C. Supernatant was separated and stored at -80°C till be assayed for estimation of hepatic malondialdehyde (MDA) content using Cayman Thiobarbituric Acid Reactive Substances assay (Cayman Chemical Co., Ann Arbor, MI, USA) [21].

- The 3<sup>rd</sup> part of the homogenate was used to prepare a cytosolic fraction of the liver by centrifugation at 10,000 x g for 15 min at 4°C using a cooling ultra-centrifuge (Sorvall

Combiplus T-880, Du Pont, USA). The obtained clear supernatant (cytosolic fraction) was used for the colorimetric estimation of glutathione peroxidase (GPx) [22], catalase (CAT) [23] and superoxide dismutase (SOD) [24] activity using Cayman assays (Cayman Chemical Co., Ann Arbor, MI, USA).

## 2.5. Histopathological examination

For light microscopic examination, liver specimen were fixed in 10% buffered formalin, (pH 7.8) and, then thin sections (4  $\mu$ m) were stained with hematoxylin-eosin (HE) for general histological features determination [25].

## 2.6. Statistical analysis

Obtained data were presented as mean $\pm$ SD, ranges, numbers and ratios. Results were analyzed using One-way ANOVA with post-hoc Tukey HSD Test and Chi-square test ( $X^2$  test). Statistical analysis was conducted using the SPSS (Version 15, 2006) for Windows statistical

package. P value <0.05 was considered statistically significant.

## 3. Results

### 3.1 Effect of carvedilol treatment on serum liver enzymes activity in acetaminophen induced acute hepatotoxicity in rats and the role of endogenous H<sub>2</sub>S

Estimated serum AST and ALT activity levels were significantly ( $p < 0.05$ ) higher in study groups compared to levels estimated in control animals. Animals of group II (APAP alone) had significantly ( $p < 0.05$ ) higher serum AST and ALT activity levels compared to groups III and IV. Interestingly, animals of group IV that received PAG injection in addition to APAP and CVD had significantly ( $p < 0.05$ ) higher serum AST and ALT activity levels compared to animals of group III that received APAP and CVD alone (Table 1).

**Table 1.** Mean serum AST and ALT activity levels estimated in animals of studied groups

Indicator	Group I	Group II	Group III	Group IV
Serum AST (U/L)	27.8 $\pm$ 4.8	1183 $\pm$ 372*	154 $\pm$ 34.1* <sup>†</sup>	205.5 $\pm$ 35.3* <sup>†#</sup>
Serum ALT (U/L)	32.3 $\pm$ 3.4	1544 $\pm$ 633*	184 $\pm$ 56.8* <sup>†</sup>	265.5 $\pm$ 59.8* <sup>†#</sup>

Data are presented as mean $\pm$  SD; Group I: Control group; Group II: acetaminophen (APAP) alone; Group III: APAP+ carvedilol (CVD); Group IV: APAP+CVD+PAG; AST: Aspartate aminotransferase; ALT: Alanine aminotransferase; \* $p < 0.05$ : significance versus group I; <sup>†</sup> $p < 0.05$ : significance versus group II; <sup>#</sup> $p < 0.05$ : significance versus group III.

### 3.2 Effect of carvedilol treatment on oxidative stress markers in acetaminophen induced acute hepatotoxicity in rats and the role of endogenous H<sub>2</sub>S

Liver homogenate MDA content was significantly ( $P=0.005$  &  $0.046$ ) higher in groups II and IV, but was non-significantly ( $p > 0.05$ ) higher in group III compared to levels estimated in animals of group I. Mean MDA content of liver homogenate of animals of group II was significantly ( $p < 0.05$ ) higher compared to levels estimated in animals of groups III and IV with significantly ( $p < 0.05$ ) higher MDA content of liver homogenate of animals of group IV compared to group III (Table 2).

Liver homogenate GSH activity levels were significantly ( $p < 0.05$ ) lower in groups II, III and IV, compared to activity levels estimated in liver homogenate of animals of group I. Mean GSH activity level of liver homogenate of animals of group II was significantly ( $p < 0.05$ ) lower compared to animals of group III, but were non-significantly ( $p > 0.05$ ) higher compared to group IV. On contrary, mean GSH activity level of liver homogenate of animals of group III were significantly ( $p < 0.05$ ) higher than in animals of group IV (Table 2).

Mean GPx activity levels estimated in liver homogenates of animals of groups II and IV were significantly ( $p < 0.05$ ) lower, but were non-significantly ( $p > 0.05$ ) lower in animals of groups

III compared to activity levels estimated in liver homogenate of animals of group I. Mean GPx activity level of liver homogenate of animals of group III and IV were significantly higher ( $p < 0.05$ ) in comparison to animals of group II, with significantly ( $p < 0.05$ ) higher activity levels in liver homogenates of animals of group III than animals of group IV (Table 2).

Liver homogenate CAT activity levels were significantly ( $p < 0.05$ ) lower in groups II, III and IV, compared to activity levels estimated in liver homogenate of animals of group I. Mean CAT activity level of liver homogenate of animals of group II was significantly ( $p < 0.05$ ) lower compared to animals of group III, but was non-significantly ( $p > 0.05$ ) lower compared to group

IV. On contrary, mean CAT activity level of liver homogenate of animals of group III were significantly ( $P3=0.032$ ) higher than in animals of group IV (Table 2).

Liver homogenate SOD activity levels were significantly ( $p < 0.05$ ) lower in groups II, III and IV, compared to activity levels estimated in liver homogenate of animals of group I. Mean SOD activity level of liver homogenate of animals of group II was significantly ( $p < 0.05$ ) lower compared to animals of group III, but was non-significantly ( $p > 0.05$ ) lower compared to group IV. On contrary, mean SOD activity level of liver homogenate of animals of group III were significantly ( $p < 0.05$ ) higher than in animals of group IV (Table 2).

**Table 2.** Mean liver homogenate MDA content and antioxidant enzyme activity levels estimated in animals of studied groups

Indicator	Group I	Group II	Group III	Group IV
MDA (mmol/g wet liver tissue)	287±49.5	822±89.2*	293.5±60.2*†	368.5±91.5*†#
GSH (mmol/g wet liver tissue)	10.17±1.8	3.77±1.06*	6.31±1.66*†	4.43±1.03*#
GPx (mmol/g wet liver tissue)	251±62.6	130±45.5*	219.5±37.2†	175.5±37.6*†#
CAT (mmol/g wet liver tissue)	104.2±13.8	65.4±13.6*	85.8±6.7*†	72±11.3*#
SOD (mmol g wet liver tissue)	8.78±0.91	5.7±1.23*	7.33±0.9*†	6.1±0.97*#

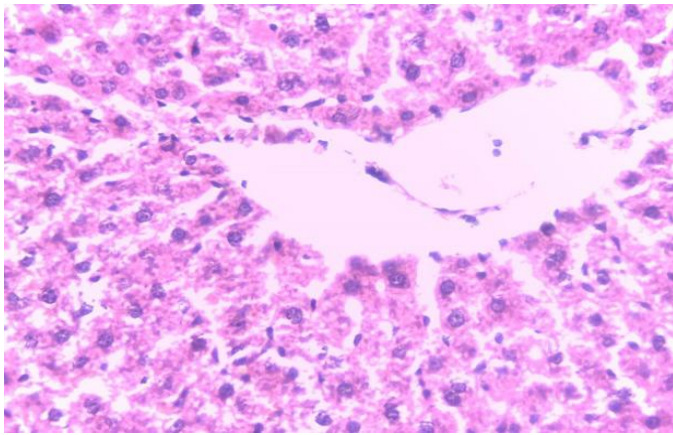
Data are presented as mean ±SD; Group I: Control group; Group II: acetaminophin (APAP) alone; Group III: APAP+ carvedilol (CVD); Group IV: APAP+CVD+PAG; MDA: Malondialdehyde; GSH: reduced glutathione; GPx: glutathione peroxidase; CAT: Catalase; SOD: superoxide dismutase; \* $p < 0.05$ : significance versus group I; † $p < 0.05$ : significance versus group II; # $p < 0.05$ : significance versus group III.

### 3.3. Histopathological Results:

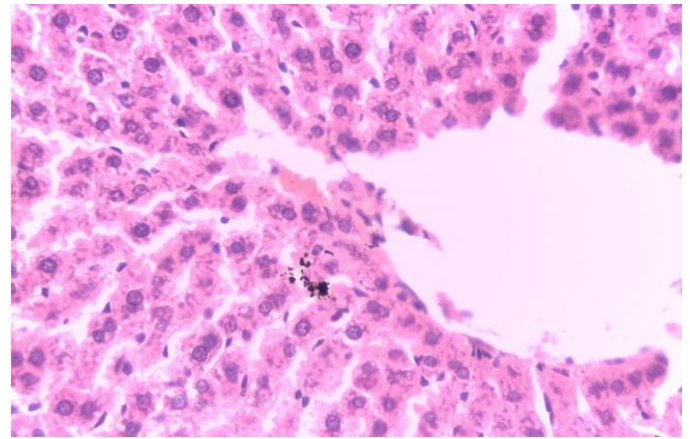
In control group (Group I), liver sections showed a normal histological structure of hepatic tissue that involved a thread like arrangement of hepatocyte cells (Figure 1A). In group II, liver specimens of rats received APAP alone exhibited wide areas of hydropic degeneration (ballooning), necro-inflammatory foci, and congestion compared to that observed in control group (Figure 1B & 1C). In group III, liver specimens of rats received CVD

for 14 days after APAP administration showed normal looking of hepatic tissue but with early congestion, minimal hydropic changes (granular cytoplasm) and rare necro-inflammatory foci (Figure 1D). In group IV, liver specimens of rats received intraperitoneal injection of PAG followed CVD after APAP administration for 14 days showed mild to moderate hydropic degeneration with cytoplasmic vacuoles and mild inflammatory cell infiltration (Figure 1E).

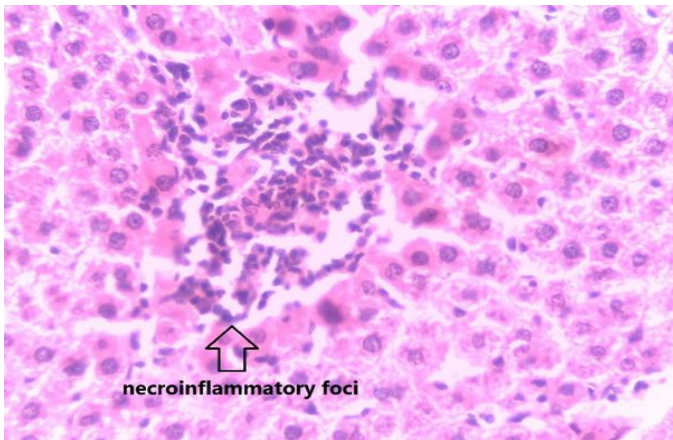




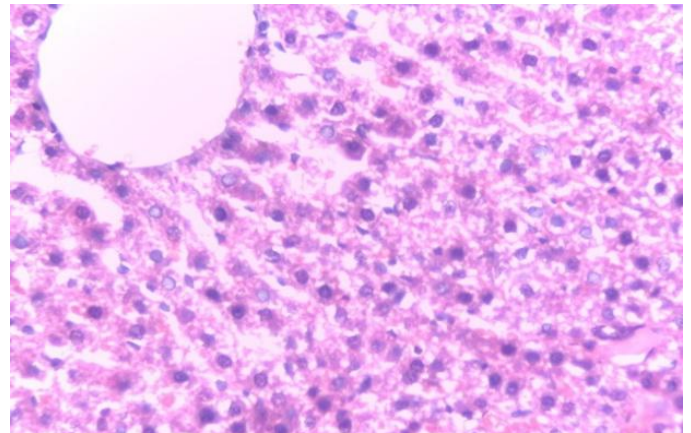
**Figure 1A.** Liver specimen of group I showing normal hepatic tissue architecture (H & E stain 40X)



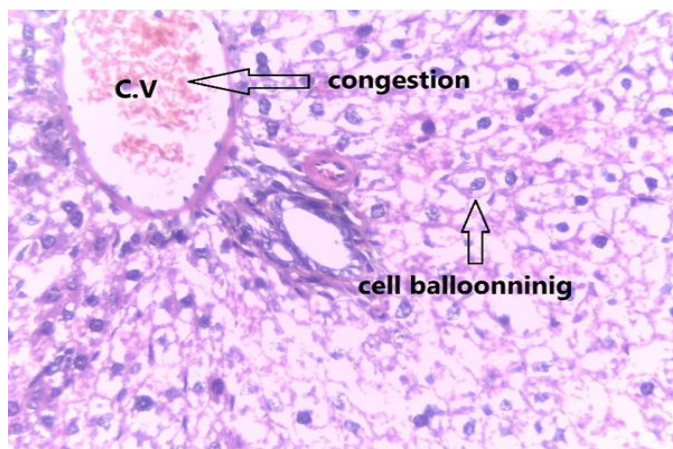
**Figure 1D.** Liver specimen of group III showing early congestion, minimal hydropic changes (granular cytoplasm) (H & E stain 40X)



**Figure 1B.** Liver specimen of group II showing necroinflammatory foci (H & E stain 40X)



**Figure 1E.** Liver specimen of group IV showing mild to moderate hydropic degeneration with cytoplasmic vacuoles and mild inflammatory cell infiltration (H & E stain 40X)



**Figure 1C.** Liver specimen of group II showing congestion of central vein (CV) and cell hydropic degeneration (cell ballooning) (H & E stain 40X)

#### 4. Discussion

The current study could approve the hepatotoxic effect of acute acetaminophen (APAP) exposure that was illustrated histologically as wide areas of hydropic degeneration, necro-inflammatory foci and congestion. Similarly, Somanawat et al., [26] found that liver of APAP-treated animals showed extensive hemorrhagic hepatic necrosis at all zones, and Soliman et al., [27] reported extensive coagulative necrosis in hepatocytes in liver of APAP intoxicated animals.

The current study also reported that APAP-induced hepatic toxicity was reflected as significantly higher levels of ALT and AST in

comparison to control animals. In line with this finding, Galal et al., [16], Alipour et al., [28], Lee et al., [29], Mahmoud et al., [30] and Bektur et al., [31] previously reported that APAP caused marked liver damage as noted by significantly increased activities of serum AST and ALT. Moreover, Hu et al., [32] found high APAP dose caused ALT release, necrosis, irreversible mitochondrial dysfunction, and hepato-cellular death.

In trial to explore the underlying mechanism for the reported toxic effect of acute APAP exposure, the current study detected significantly higher levels of MDA with significantly lower levels and activity of GSH, GPx, CAT and SOD in liver homogenates of study animals compared to control animals. These findings go in hand with Galal et al., [16] and Somanawat et al., [26] who reported that APAP caused a significant decrease in liver GSH and GPx activity which paralleled the increase in MDA levels and with Alipour et al., [28] who detected increased tissue levels of lipid peroxidation products with decreases in hepatic levels of reduced GSH, GSH peroxidase and reductase. Recently, Ding et al., [4] reported disturbed hepatic tissue antioxidant activities with increasing hepatic MDA contents and reducing hepatic tissue SOD, GSH-PX and GSH activity, Saeedi Saravi et al., [33] also reported that oral APAP decreased GSH and SOD activities.

Fortunately, the use of carvedilol (CVD) significantly reduced the manifestations of acute APAP toxicity manifested as significantly lower serum AST, ALT levels and levels of MDA in liver homogenates with preserved levels of antioxidant enzyme levels in liver homogenate compared to study animals; despite being still significantly altered compared to control animals. This effect of CVD was approved histologically where only minimal changes were detected in the studied liver specimens.

These findings go in hand with Zubairi et al., [34] who detected histopathological changes of hepatotoxicity in all APAP-treated rabbits, but completely disappeared in 50%, while was mild in 50% of CVD-treated rabbits. Also, they found serum liver function tests and MDA in serum and liver homogenate were elevated with depleted GSH after APAP treatment, in CVD-treated rabbits while MDA and ALP levels were significantly decreased.

The preserved levels of activity of antioxidant enzymes and the decreased levels of MDA in liver homogenates point to an antioxidant activity of CVD and assured the fact that disturbances of oxidant/antioxidant milieu in hepatic tissue underlies acute APAP hepatotoxicity. Moreover, Hamdy N & El-Demerdash [10] attributed the antifibrotic effects of CVD to amelioration of oxidative stress through mainly, replenishment of GSH, restoration of antioxidant enzyme activities and reduction of lipid peroxides as well as amelioration of inflammation and fibrosis by decreasing collagen accumulation, acute phase protein level, NF- $\kappa$ B expression and finally hepatic stellate cell activation.

In support of antioxidant activity of CVD, Ozaydin et al., [35] clinically detected that CVD and N-acetyl cysteine reduced oxidative stress and inflammation compared with metoprolol and decreased oxidative stress compared with CVD alone. Recently, Araújo Júnior et al., [36] in rat model of ethanol-induced liver injury reported that CVD treatment was associated with reduced levels of AST, ALT, triglyceride, MDA, and pro-inflammatory cytokines and increased levels of the anti-inflammatory cytokine IL-10 and GSH compared to the alcohol-only group

Interestingly, animals received CVD and H<sub>2</sub>S blocker (PAG) showed deterioration of the effect of CVD manifested as significantly higher serum levels of ALT, AST and MDA levels with reduced activity levels of antioxidant enzymes in liver homogenates compared to animals received CVD alone despite being significantly better than animals received APAP alone. Such deterioration was also assured histologically and indicated an ameliorative effect of naturally synthesized H<sub>2</sub>S on APAP toxic effects. Also, these findings indicated an ability of naturally synthesized H<sub>2</sub>S to preserve the body antioxidant reserve despite of toxic exposure. However, the reported data in the study group indicated a fact that endogenous H<sub>2</sub>S activity could not withstand for acute exposure, thus it could explain the absence or the indefinite toxic manifestations of intermittent or temporary APAP exposure.

These data supported the recently documented effects of H<sub>2</sub>S where Okamoto et al., [37] suggested that H<sub>2</sub>S produced by CSE is a part of a homeostatic

mechanism used by pancreatic  $\beta$ -cells to inhibit insulin release and reduce cellular stress evoked by glucose, possibly via the  $H_2S$  anti-oxidant properties. Sodha and Sellke [38] documented that administration of  $H_2S$  as a therapeutic agent in the setting of ischemia-reperfusion can markedly attenuate the inflammatory response with subsequent mitigation of tissue injury and improved function. Dief et al., [39] found that treatment with ATB-346, a novel  $H_2S$ -releasing naproxen, attenuated nociceptive responses, inflammatory cellular and biochemical changes in comparison to naproxen and ATB-346 was able to suppress neutrophil adherence and to preserve normal articular structure, while naproxen showed deleterious effects on articular cartilage. The number of the study animals (forty animals) might not represent the variations in response to carvedilol treatment and the side effects that can result from such treatment. So the authors recommend doing further studies in large scales.

## 5. Conclusion

Acute APAP exposure is hepatotoxic through inducing alterations of oxidant/antioxidant milieu leading to destroyed hepatic architecture and altered liver function tests. CVD has a curative effect against acute APAP hepatotoxicity through preservation of activity of antioxidants. We also demonstrated for a finding that endogenous  $H_2S$  significantly contributes toward CVD mediated action against APAP hepatotoxicity.

## References

1. Maes M, Vinken M, Jaeschke H: Experimental models of hepatotoxicity related to acute liver failure. *Toxicol Appl Pharmacol.* 2016; 290:86-97. [Doi: 10.1016/j.taap.2015.11.016](https://doi.org/10.1016/j.taap.2015.11.016)
2. Eugenio-Pérez D, Montes de Oca-Solano HA, Pedraza-Chaverri J: Role of food-derived antioxidant agents against acetaminophen-induced hepatotoxicity. *Pharm Biol.* 2016; 54(10):2340-52. [DOI: 10.3109/13880209.2016.1150302](https://doi.org/10.3109/13880209.2016.1150302)
3. Barman PK, Mukherjee R, Prusty BK, Suklabaidya S, Senapati S, Ravindran B: Chitohexaose protects against acetaminophen-induced hepatotoxicity in mice. *Cell Death Dis.* 2016; 7:e2224. [DOI: 10.1038/cddis.2016.131](https://doi.org/10.1038/cddis.2016.131)
4. Ding Y, Li Q, Xu Y, Chen Y, Deng Y, Zhi F, Qian K: Attenuating Oxidative Stress by Paeonol Protected against Acetaminophen-Induced Hepatotoxicity in Mice. *PLoS One.* 2016; 11(5):e0154375. [DOI: 10.1371/journal.pone.0154375](https://doi.org/10.1371/journal.pone.0154375)
5. Boonruamkaew P, Chonpathompikunlert P, Nagasaki Y: Redox Nanoparticle Therapeutics for Acetaminophen-Induced Hepatotoxicity in Mice. *Oxid Med Cell Longev.* 2016; 2016:4984597. [Doi.org/10.1155/2016/4984597](https://doi.org/10.1155/2016/4984597)
6. Brody TM, Calvert DN, Schneider AF. Alteration of carbon tetrachloride-induced pathologic changes in the rat by spinal transection, adrenalectomy and adrenergic blocking agents. *J Pharmacol Exp Ther.* 1961;131:341–345.
7. Iwai M and Shimazu T: Effects of ventromedial and lateral hypothalamic stimulation on chemically-induced liver injury in rats. *Life Sci.* 1988; 42(19):1833-40. [PMID: 3367688](https://pubmed.ncbi.nlm.nih.gov/3367688/)
8. Arozal W, Watanabe K, Veeraveedu PT, Ma M, Thandavarayan RA, Sukumaran V, et al.: Protective effect of carvedilol on daunorubicin-induced cardiotoxicity and nephrotoxicity in rats. *Toxicology*, 2010; 274: 18–26. [DOI: 10.1016/j.tox.2010.05.003](https://doi.org/10.1016/j.tox.2010.05.003)
9. Li YC, Ge LS, Yang PL, Tang JF, Lin JF, Chen P, et al.: Carvedilol treatment ameliorates acute coxsackievirus B3-induced myocarditis associated with oxidative stress reduction. *Eur J Pharmacol.*, 2010; 640: 112–116. [DOI: 10.1016/j.ejphar.2010.04.037](https://doi.org/10.1016/j.ejphar.2010.04.037)
10. Hamdy N and El-Demerdash E: New therapeutic aspect for carvedilol: antifibrotic effects of carvedilol in chronic carbon tetrachloride-induced liver damage. *Toxicol Appl Pharmacol.* 2012; 261(3):292-9. [DOI: 10.1016/j.taap.2012.04.012](https://doi.org/10.1016/j.taap.2012.04.012)
11. Liu J, Takase I, Hakucho A, Okamura N, Fujimiya T: Carvedilol attenuates the progression of alcohol fatty liver disease in rats. *Alcohol Clin Exp Res.*, 2012; 36: 1587–99. [DOI: 10.1111/j.1530-0277.2012.01773.x](https://doi.org/10.1111/j.1530-0277.2012.01773.x)



12. Wu D, Hu Q, Zhu Y: Therapeutic application of hydrogen sulfide donors: the potential and challenges. *Front Med.* 2016; 10(1):18-27. [DOI: 10.1007/s11684-015-0427-6](https://doi.org/10.1007/s11684-015-0427-6)
13. Calderone V, Martelli A, Testai L, Citi V, Breschi MC: Using hydrogen sulfide to design and develop drugs. *Expert Opin Drug Discov.* 2016; 11(2):163-75. [DOI: 10.1517/17460441.2016.1122590](https://doi.org/10.1517/17460441.2016.1122590)
14. Wallace JL, Blackler RW, Chan MV, Da Silva GJ, Elsheikh W, Flannigan KL, Gamaniek I, Manko A, Wang L, Motta JP, Buret AG: Anti-inflammatory and cytoprotective actions of hydrogen sulfide: translation to therapeutics. *Antioxid Redox Signal.* 2015; 22(5):398-410. [DOI: 10.1089/ars.2014.5901](https://doi.org/10.1089/ars.2014.5901)
15. Akter F: The role of hydrogen sulfide in burns. *Burns.* 2016; 42(3):519-25. [DOI: 10.1016/j.burns.2015.07.005](https://doi.org/10.1016/j.burns.2015.07.005)
16. Galal RM, Zaki HF, Seif El-Nasr MM, Agha AM: Potential protective effect of honey against paracetamol-induced hepatotoxicity. *Arch Iran Med.* 2012; 15(11):674-80.
17. Rajesh P: Antioxidant Property of Antihypertensive Drugs (Carvedilol, Enalapril, and Amlodipine) On Liver Function In Animal (Rats) Models. *Asian J Pharm Clin Res.* 2016; 9, Suppl. 2, 292-293. [DOI:http://dx.doi.org/10.22159/ajpcr.2016.v9s2.13924](https://doi.org/http://dx.doi.org/10.22159/ajpcr.2016.v9s2.13924)
18. Fan HN, Chen NW, Shen WL, Zhao XY, And Zhang J: Endogenous hydrogen sulfide is associated with angiotensin II type 1 receptor in a rat model of carbon tetrachloride-induced hepatic fibrosis. *Mol Med Rep.* 2015; Sep; 12(3): 3351–3358. Doi: [10.3892/mmr.2015.3873](https://doi.org/10.3892/mmr.2015.3873)
19. Zilva JF and Pannall PR. *Plasma Enzymes in Diagnosis in Clinical Chemistry in Diagnosis and Treatment.* Lloyd-Luke London. 1979; Chap 15:338-9.
20. Lash LH and Jones DP: Distribution of oxidized and reduced forms of glutathione and cysteine in rat plasma. *Arch Biochem Biophys.* 1985; 240(2):583-92. [PMID: 4026295](https://pubmed.ncbi.nlm.nih.gov/4026295/)
21. Armstrong D and Browne R: Free radicals in diagnostic medicine. 1994, 366; 43-58
22. Ursini F, Maiorino M, Gregolin C: The Selenoenzyme phospholipid hydroperoxide glutathione peroxidase. *Biochim. Biophys. Acta,* 1985; 839: 62-70. [PMID: 3978121](https://pubmed.ncbi.nlm.nih.gov/3978121/)
23. Johansson LH and Borg LAH: A spectrophotometric method for determination of catalase activity in small tissue samples. *Anal. Biochem.,* 1988; 174: 331-6.
24. Marklund S: Distribution of CuZn superoxide dismutase and Mn superoxide dismutase in human tissues and extracellular fluids. *Acta Physiol. Scand.,* 1980; Suppl. 492: 19-23. [PMID: 6939305](https://pubmed.ncbi.nlm.nih.gov/6939305/)
25. Bancroft JD and Gamble M: *Theory and practice of histological techniques.* 5<sup>th</sup> ed., Churchill Livingstone. London, New York & Sydney, 2002; 377& 694.
26. Somanawat K, Thong-Ngam D, Klaikeaw N: Curcumin attenuated paracetamol overdose induced hepatitis. *World J Gastroenterol.* 2013; 19(12):1962-7. [DOI: 10.3748/wjg.v19.i12.1962](https://doi.org/10.3748/wjg.v19.i12.1962)
27. Soliman MM, Abdo Nassan M, Ismail TA: Immunohistochemical and molecular study on the protective effect of curcumin against hepatic toxicity induced by paracetamol in Wistar rats. *BMC Complement Altern Med.* 2014; 14:457. [DOI: 10.1186/1472-6882-14-457](https://doi.org/10.1186/1472-6882-14-457)
28. Alipour M, Buonocore C, Omri A, Szabo M, Pucaj K, Suntres ZE: Therapeutic effect of liposomal-N-acetylcysteine against acetaminophen-induced hepatotoxicity. *J Drug Target.* 2013; 21(5):466-73. [DOI: 10.3109/1061186X.2013.765443](https://doi.org/10.3109/1061186X.2013.765443)
29. Lee KK, Imaizumi N, Chamberland SR, Alder NN, Boelsterli UA: Targeting mitochondria with methylene blue protects mice against acetaminophen-induced liver injury. *Hepatology.* 2015; 61(1):326-36. [DOI: 10.1002/hep.27385](https://doi.org/10.1002/hep.27385)
30. Mahmoud YI, Mahmoud AA, Nassar G: Alpha-lipoic acid treatment of acetaminophen-induced rat liver damage. *Biotech Histochem.* 2015;90(8):594-600. [DOI: 10.3109/10520295.2015.1063005](https://doi.org/10.3109/10520295.2015.1063005)
31. Bektur NE, Sahin E, Baycu C, Unver G: Protective effects of silymarin against acetaminophen-induced hepatotoxicity and nephrotoxicity in mice. *Toxicol Ind Health.*

- 2016; 32(4):589-600. [DOI: 10.1177/0748233713502841](#)
32. Hu J, Ramshesh VK, McGill MR, Jaeschke H, Lemasters JJ: Low Dose Acetaminophen Induces Reversible Mitochondrial Dysfunction Associated with Transient c-Jun N-Terminal Kinase Activation in Mouse Liver. *Toxicol Sci.* 2016; 150(1):204-15. [DOI: 10.1093/toxsci/kfv319](#)
  33. Saeedi Saravi SS, Hasanvand A, Shahkarami K, Dehpour AR: The protective potential of metformin against acetaminophen-induced hepatotoxicity in BALB/C mice. *Pharm Biol.* 2016 Jun 1:1-8. [Epub ahead of print]. [DOI: 10.1080/13880209.2016.1185633](#)
  34. Zubairi MB, Ahmed JH, Al-Haroon SS: Effect of adrenergic blockers, carvedilol, prazosin, metoprolol and combination of prazosin and metoprolol on paracetamol-induced hepatotoxicity in rabbits. *Indian J Pharmacol.* 2014; 46(6):644-8. [DOI: 10.4103/0253-7613.144937](#)
  35. Ozaydin M, Peker O, Erdogan D, Akcay S, Yucel H, Icli A, Ceyhan BM, Sutcu R, Uysal BA, Varol E, Dogan A, Okutan H: Oxidative status, inflammation, and postoperative atrial fibrillation with metoprolol vs carvedilol or carvedilol plus N-acetyl cysteine treatment. *Clin Cardiol.* 2014; 37(5):300-6. [Doi: 10.1002/clc.22249.](#)
  36. Araújo Júnior RF, Garcia VB, Leitão RF, Brito GA, Miguel Ede C, Guedes PM, de Araújo AA: Carvedilol Improves Inflammatory Response, Oxidative Stress and Fibrosis in the Alcohol-Induced Liver Injury in Rats by Regulating Kuppfer Cells and Hepatic Stellate Cells. *PLoS One.* 2016; 11(2):e0148868. [Doi: 10.1371/journal.pone.0148868.](#)
  37. Okamoto M, Ishizaki T, Kimura T: Protective effect of hydrogen sulfide on pancreatic beta-cells. *Nitric Oxide.* 2015; 46:32-6. [DOI: 10.1016/j.niox.2014.11.007](#)
  38. Sodha NR and Sellke FW: Attenuation of inflammatory responses by hydrogen sulfide (H<sub>2</sub>S) in ischemia/reperfusion injury. *Methods Enzymol.* 2015; 555:127-44. [DOI: 10.1016/bs.mie.2014.11.041](#)
  39. Dief AE, Mostafa DK Sharara GM, Zeitoun TH: Hydrogen sulfide releasing naproxen offers better anti-inflammatory and chondroprotective effect relative to naproxen in a rat model of zymosan induced arthritis. *Eur Rev Med Pharmacol Sci.* 2015; 19(8):1537-46. [PMID: 25967731.](#)